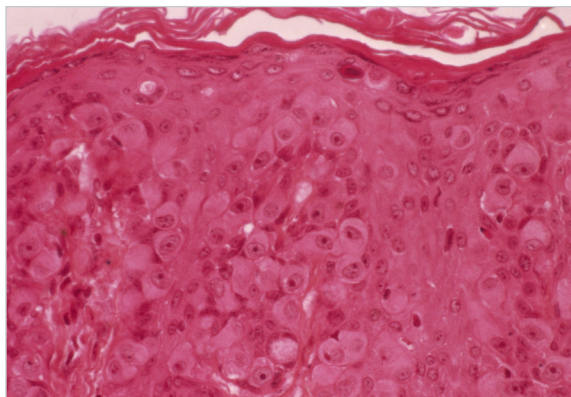


Paget Disease of the Breast



What is Paget disease of the breast?

Paget disease of the breast (also known as Paget disease of the nipple and mammary Paget disease) is a rare type of cancer involving the skin of the nipple and, usually, the darker circle of skin around it, which is called the areola. Most people with Paget disease of the breast also have one or more tumors inside the same breast. These breast tumors are either ductal carcinoma in situ or invasive breast cancer.¹⁻³

Paget disease of the breast is named after the 19th century British doctor Sir James Paget, who, in 1874, noted a relationship between changes in the nipple and breast cancer.

Malignant cells known as Paget cells are a telltale sign of Paget disease of the breast. These cells are found in the epidermis (surface layer) of the skin of the nipple and the areola. Paget cells often have a large, round appearance under a microscope; they may be found as single cells or as small groups of cells within the epidermis.

Who gets Paget disease of the breast?

Paget disease of the breast occurs in both women and men, but most cases

occur in women. Approximately 1 to 4 percent of all cases of breast cancer also involve Paget disease of the breast. The average age at diagnosis is 57 years, but the disease has been found in adolescents and in people in their late 80s.^{2,3}

What causes Paget disease of the breast?

Doctors do not fully understand what causes Paget disease of the breast. The most widely accepted theory is that cancer cells from a tumor inside the breast travel through the milk ducts to the nipple and areola. This would explain why Paget disease of the breast and tumors inside the same breast are almost always found together.^{1,3}

A second theory is that cells in the nipple or areola become cancerous on their own.^{1,3}

What are the symptoms of Paget disease of the breast?

The symptoms of Paget disease of the breast are often mistaken for those of some benign skin conditions, such as dermatitis or eczema.¹⁻³ These symptoms may include the following:

- Itching, tingling, or redness in the

nipple and/or areola

- Flaking, crusty, or thickened skin on or around the nipple
- A flattened nipple
- Discharge from the nipple that may be yellowish or bloody

Because the early symptoms of Paget disease of the breast may suggest a benign skin condition, and because the disease is rare, it may be misdiagnosed at first.

How is Paget disease of the breast diagnosed?

A nipple biopsy allows doctors to correctly diagnose Paget disease of the breast. There are several types of nipple biopsy, including the procedures described below.

- Surface biopsy: A glass slide or other tool is used to gently scrape cells from the surface of the skin.
- Shave biopsy: A razor-like tool is used to remove the top layer of skin.
- Punch biopsy: A circular cutting tool, called a punch, is used to remove a disk-shaped piece of tissue.
- Wedge biopsy: A scalpel is used to remove a small wedge of tissue.

In some cases, doctors may remove the entire nipple.¹ A pathologist then



examines the cells or tissue under a microscope to look for Paget cells.

Most people who have Paget disease of the breast also have one or more tumors inside the same breast. In addition to ordering a nipple biopsy, the doctor should perform a clinical breast exam to check for lumps or other breast changes. As many as 50 percent of people who have Paget disease of the breast have a breast lump that can be felt in a clinical breast exam. The doctor may order additional diagnostic tests, such as a diagnostic mammogram, an ultrasound exam, or a MRI to look for possible tumors.^{1,2}

How is Paget disease of the breast treated?

For many years, mastectomy, with or without the removal of lymph nodes under the arm on the same side of chest (known as axillary lymph node dissection), was regarded as the standard surgery for Paget disease of the breast.^{3,4}

Studies have shown, however, that breast-conserving surgery that includes removal of the nipple and areola, followed by whole-breast radiation therapy, is a safe option for people with Paget disease of the breast who do not have a

palpable lump in their breast and whose mammograms do not reveal a tumor.³⁻⁵

People with Paget disease of the breast who have a breast tumor and are having a mastectomy should be offered sentinel lymph node biopsy to see whether the cancer has spread to the axillary lymph nodes. If cancer cells are found in the sentinel lymph node(s), more extensive axillary lymph node surgery may be needed.^{1,6,7} Depending on the stage and other features of the underlying breast tumor, adjuvant therapy, consisting of chemotherapy and/or hormonal therapy, may also be recommended.

Selected References

1. Harris JR, Lippman ME, Morrow M, Osborne CK, editors. *Diseases of the Breast*. 4th ed. Philadelphia: Lippincott Williams & Wilkins; 2009.
2. Caliskan M, Gatti G, Sosnovskikh I, et al. Paget's disease of the breast: the experience of the European Institute of Oncology and review of the literature. *Breast Cancer Research and Treatment* 2008;112(3):513-521.
3. Kanitakis J. Mammary and extramammary Paget's disease. *Journal of the European Academy of Dermatology and Venereology* 2007;21(5):581-590.
4. Kawase K, Dimaio DJ, Tucker SL, et al. Paget's disease of the breast: there is a role for

breast-conserving therapy. *Annals of Surgical Oncology* 2005;12(5):391-397.

5. Marshall JK, Griffith KA, Haffty BG, et al. Conservative management of Paget disease of the breast with radiotherapy: 10- and 15-year results. *Cancer* 2003;97(9):2142-2149.

6. Sukumvanich P, Bentrem DJ, Cody HS, et al. The role of sentinel lymph node biopsy in Paget's disease of the breast. *Annals of Surgical Oncology* 2007;14(3):1020-1023.

7. Laronga C, Hasson D, Hoover S, et al. Paget's disease in the era of sentinel lymph node biopsy. *American Journal of Surgery* 2006;192(4):481-483.

8. Ries LAG, Eisner MP. Cancer of the Female Breast. In: Ries LAG, Young JL, Keel GE, et al., editors. *SEER Survival Monograph: Cancer Survival Among Adults: U.S. SEER Program, 1988-2001, Patient and Tumor Characteristics*. Bethesda, MD: National Cancer Institute, SEER Program, 2007. Retrieved April 10, 2012.

9. Chen CY, Sun LM, Anderson BO. Paget disease of the breast: changing patterns of incidence, clinical presentation, and treatment in the U.S. *Cancer* 2006;107(7):1448-1458.

10. Joseph KA, Ditkoff BA, Estabrook A, et al. Therapeutic options for Paget's disease: a single institution long-term follow-up study. *Breast Journal* 2007;13(1):110-111.

Source: National Cancer Institute.

RELATED FACT SHEET

You may be interested in the following fact sheets from *Oncology Nurse Advisor*

- **Surgery to Reduce the Risk of Breast Cancer** <http://bit.ly/2hLfH0x>
- **Adjuvant and Neoadjuvant Therapy for Breast Cancer** <http://bit.ly/2kjeYVf>
- **Breast Cancer Risk in American Women** <http://bit.ly/2xdD7T6>